

Lucy Edmonton Valley Zoo
October 5-7, 2003
Patricia London, DVM on behalf of Free the Wild

Part 1: Overall Health Assessment

Aim: To perform an in-depth assessment on the overall health and psychological wellbeing of Lucy with a view to provide treatment and long-term care options for any ailments and stressors that could be affecting her in day-to-day life.

I observed Lucy October 5-7 2022. Due to the observers present and procedures done during this time this may not be completely reflective of her 'normal' routine and life.

Lucy (Skanik), 47 year old female Asian elephant, nulliparous (though two attempts were previously made to breed her at another zoo many years ago).

Subjective:

Bright, alert, and responsive. Mucous membranes pink /moist, keepers report normal appetite and thirst, visualized normal urination and defecation frequency and amount. Some undigested/unchewed material present in fecal boluses.



Lucy is very inquisitive and calm about everything going on around her, but also a bit slow, bored, and disconnected in general.

Diet: 50-60 lbs of hay is offered daily along with beet pulp, Mazuri hay enhancer, an unknown/unrecorded amount of monkey chow, air popped popcorn with salt, and a variety of branches when available. Her appetite appears to be normal.

Supplements: Spirulina (5 scoops), Hoofmaster (1 scoop-biotin, vitamins, minerals), E sel (2 scoops), Ubavet (glucosamine) 6 pumps, and a Legend injection monthly.

Current Medications: Previcox (NSAID) 454 mg PO SID started 5/11/22

Age: At 47, Lucy is often referred to as a geriatric/elderly elephant. This representation is incorrect as, in truth, she is a mature adult and only middle aged. It is not uncommon and

absolutely possible for elephants to live into their 70s or 80s in Asia and the wild. Unfortunately, the effects of captivity on elephants in zoos and circuses decreases the average lifespan for elephants in western zoos to only 27.5 years. As a result, given the aforementioned, it is acknowledged that Lucy is older for an elephant in captivity in a zoo, but this should not be portrayed incorrectly as geriatric. The median lifespan for elephants born in captivity within the U.K. is less than 20 years, approximately half that of their wild conspecifics (Mason & Veasey, 2010), while the median lifespan for elephants in North America is 43 years for Asian elephants and 39 years for African elephants (Elephant Database). At present, no captive elephants in North America or Europe have reached the maximum ages seen in the wild (75-80 years) (Lee et al., 2013). (Elephants in Zoos, Born Free)

Objective:

Physical exam

Body condition score: Lucy has a body condition score 5/5 (obese) (i.e. ribs not visible, pelvic bone not visible, backbone not visible or difficult to differentiate, area alongside backbone is filled in giving a round appearance. Most recent scale weight of 9385 lbs on 10/31/22.



Eyes: Bright and open with no discharge

Ears: No discharge noted although there is a documented history of ear infections from review of her medical records

Mouth: Absent tushes – no evidence on ultrasound of tushes in sulcus

Nose: Discharge from trunk. Strong foul smelling discharge from trunk on walk. No noise/cough associated with the appearance of the discharge, it just appears on the ground from her trunk. Reportedly no change in the color or amount of nasal discharge with the seasons.



She has a history of discharge from her trunk since 2005 which is noted in her medical records. The frequency, amount, color, smell, and consistency of the discharge changes but never reportedly resolved/improved with antibiotics, mucolytics (Dembrexine hydrochloride) or antihistamines (diphenhydramine). Last course of antibiotics for trunk discharge was 04/12/2016 with TMS for nasal discharge. She has never been treated with antifungals.

Respiratory: Lucy's resting respiratory rate is 4 breaths/minute with a very loud rattling sound heard during expiration, which is unusual. She sometimes has a slight wheezing sound heard on inspiration. Lucy's breathing can be heard anywhere in her barn and from hundreds of meters away.

When standing, her length of inspiration is 3 seconds, expiration time 3 seconds, respiratory rate 2-4 breaths/minute. When sleeping, inspiration 2-3 seconds, expiration 3-5 seconds, RR 6-8 breaths /minute.

When walking up the hill to the dome, her respiratory rate did increase from 4 to 8-12 breaths/minute, which is still within normal limits and not tachypneic (fast). She showed no signs of respiratory distress during the walk.

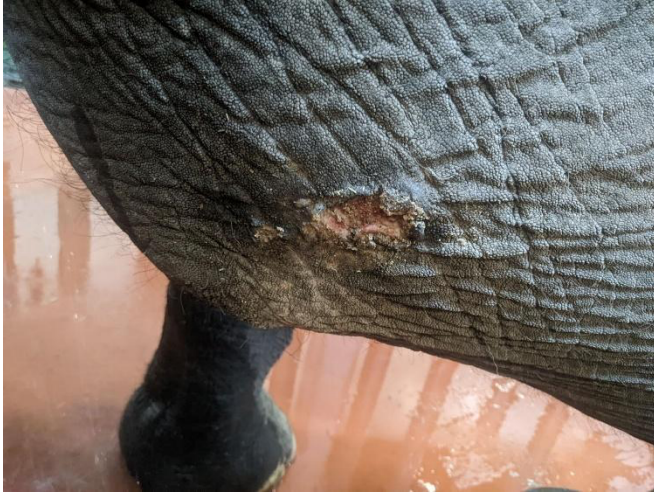When lying down during her nap, she does puff her cheeks out with expiration and her cheeks do get sucked in on inspiration, so she does appear to be only mouth breathing. Interestingly, her cheeks are almost always puffed out in between breaths as well.

She does stop eating when exhaling and inhaling. Lucy reportedly does not drink with her trunk and only from a hose placed in her mouth. As for vocalizations, she has the ability to rumble and roar.

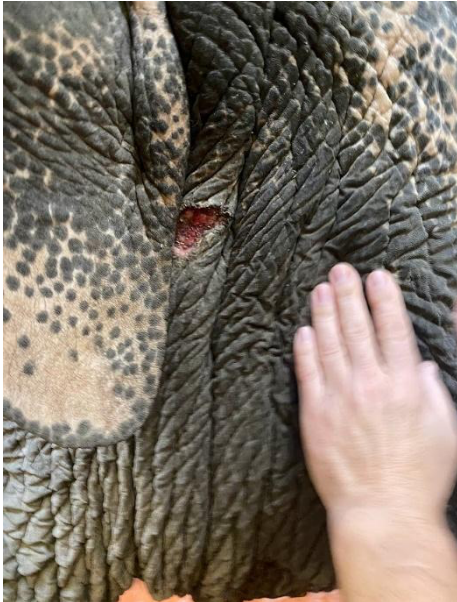Pulse ox low 90s when placed on trunk septum.

Skin: Very short tail hair. Pressure/non healing wounds right side hip, below ear and elbow, (medical notes show elbow wound first noted in 2014).

Her skin is free of dead skin buildup, not cracked or dry, and free of folliculitis.



Close up of right elbow



Close up of Lucy's right pressure sore near ear

Cold laser treatment is currently being applied several times a week to her pressure sores.


Gastrointestinal: Malocclusion of molars – left maxillary molar is rotated 90 degrees from normal. Right maxillary molar is rotated laterally and not flush. Debris can be seen caught around the teeth. Normal occlusion surface ridges on visualized teeth. Feces did show large fecal boluses with some undigested long strands which were assumed to be bark from branches given recently.



With her abnormal position of her teeth, it is imperative that her feces be monitored for increasing size and decreased digestion of fodder. She is already passing some fecal boluses with undigested/chewed material.

Lucy's medical records show since 2010 Lucy has a history of possible colic issues with abdominal pain (stretching, lying down) and anorexia managed with a variety of intermittent pain meds as necessary.

Musculoskeletal/feet: Lucy displays a slow stiff gait when she walks with weight in hind limbs applied first on the outside of her back feet, then rolling inside and walking with a slight bow-legged stance. She was sometimes noted to be dragging her hind feet when walking in the grass. Lameness is present when walking, especially downhill. Her gait presents as abnormal, with her hips dropping down on both sides with audible clicking noted at times. She has a history of an abscess on her right front foot (3rd nail). Feet and nails looked in good condition externally and from a distance during this visit.





Her tail is crooked and assumed to be from possible previous injury/trauma.

Urogenital: No discharge noted during exam, normal urination visualized with normal amount, color, and smell as well as normal urination process. History of vaginal mucoid bloody discharge.

Mental well-being: Lucy is not permitted to do anything on her own and her daily life is lacking in any autonomy. Control over her behaviors is so significant that it even includes Lucy going to the bathroom in the drain where she has been trained to go, and being rewarded for doing so. While on walks she is continuously being touched and nudged to move forward, even at times when she is stopped and contently grazing. While there is reason for caution in areas of the zoo where she could cause damage (e.g. picnic tables, Christmas lights, or injure the visiting public) there were several instances where she was grazing in a safe spot, where she could not hurt anything or anyone, and was still being touched and controlled. While some of this prodding may be to keep her walking so she gets what has been determined the appropriate amount of exercise, she is not able to enjoy quiet moments of uncontrolled behavior. During moments when she is grazing, the keepers come up to her constantly offering her food instead of allowing her to do what she wants to do – behavior that is natural for her species. This human behavior has existed for such an extended time that Lucy now responds to any caregiver approach by opening her mouth. If the goal is to continue to encourage her to move, the staff is positively reinforcing an undesired behavior. After walking to her exercise dome, Lucy is then guided to lie down to nap, and reportedly, the caretakers sometimes lie down beside her. Within thirty seconds of Lucy waking up and rising, her caretakers are right back beside her.

Exercise: Lucy is taken on a daily walk of 60-360 mins and 0.5-5 km depending on the weather conditions. Keepers maintain daily detailed records of weather conditions and walk lengths and times. There was discussion of a wooded area that she can go into and explore; however, as shared by the keepers, this area is accessed infrequently because staff are afraid that she may hurt herself on the hills.

Housing: The elephant house where Lucy spends the majority of her time is very small, approximately 250 m² total. No option for protected contact exists with current facility construction. As is common in public facilities, it appears that her exhibit was built with visitors in mind and not based on the well-being or needs of the species or individual.

One room in her enclosure has a sand bed but the sand is very coarse and contains small pebbles. The rest of her barn is concrete flooring. Rubber pad had been applied in the past,

but Lucy has removed a significant portion by pulling it up. The padding that does remain is very thin and not appreciable to be adding any comfort or cushion for her.

Lucy has access to some trees to scratch on and some dirt/mud piles that can be used for dusting but only during the time she is going for her walks. She is not being provided with the space, socialization opportunities, or natural environment conditions to meet her needs or that of her species.



When in her barn, enrichment currently provided includes haynets, tires, logs, and ball puzzle feeders. All of these enrichment items are in the small hallway that technically should be the keeper area if the facility was set up for protected contact management. It appears she is provided with the same enrichment every day creating an environment of predictability and monotony.

In the dome, There were also many “enrichment” items that did not focus on encouraging natural behavior of the species and instead were geared more towards human enjoyment. These items include drums, paint, soccer balls, and chimes. While enrichment is necessary in habitats void of stimulation, if the correct environment is provided, artificial enrichment is not required.

Lucy is housed alone in her barn for 12+ hours a day, most of the year, with no outside access because of inclement and frigid weather. I personally reviewed the camera footage from one overnight. The camera is stationarily focused solely on her sleeping pile and did not allow for visualization of anything but her sand pile. During the reviewed overnight video, she could be seen standing, and what appeared to be swaying, for about 20 minutes. This suggests she has developed stereotypic behavior which has been confirmed in other written evaluations and reports by witnesses. When we were with Lucy, she always had at least two people constantly interacting with her, which may have been to prevent her from displaying this stereotypical behavior.

Stereotypic behaviors are often indicators of compromised welfare (*Mason G.J. & Veasey J.S. (2010). How should the psychological wellbeing of zoo elephants be objectively investigated? Zoo Biology 29, 237–255*). These behaviors are a consequence of long-term

psychological damage. Living in an impoverished, stressful captive environment results in physical damage to the brain. These changes have been documented in many species, including elephants, large primates, large marine mammals, rodents, rabbits, cats, and humans (Jacobs, B. (2020). "The Neural Cruelty of Captivity: Keeping Large Mammals in Zoos and Aquariums Damages Their Brains." *The Science Times*).

During the hours we were with Lucy, she had constant attention which didn't allow her any autonomy, independence or the opportunity to explore on her own. She was never given access to, or showed any interest, in going out to either of her yards during my visit.

Medical Assessment / Problem list:

Obesity (5/5 Body Condition Score)
Respiratory noise/discharge
Pressure sores right ear, elbow and hip
Malocclusion of molars
Arthritis/lameness
h/o Nail abscess right front foot
h/o Episodes of abdominal pain

Tests performed during/after evaluation

1) Venous Blood Gas (pre exercise)
PCO₂ 53.5 (45-50)
PO₂ 45 (33-53)
SO₂ 82 (54-69)
Lac 0.95

Venous Blood Gas (post exercise)
PCO₂ 68.2 (45-50)
PO₂ 19 (33-53)
SO₂ 23 (54-69)
Lac 2.83

Two samples were taken pre and post playing "hide and go seek" with her keepers. Samples were taken from a vein, not an artery (which is proper protocol for blood gases) so these samples cannot be viewed as an accurate measurement of blood oxygen (arterial) levels.

SO₂ is not a measure of oxygenation but considered a measure of tissue perfusion or oxygen delivery. PaO₂ is a measure of how well oxygen exchange is happening in the lungs, which is and not measured during this testing because samples were venous.

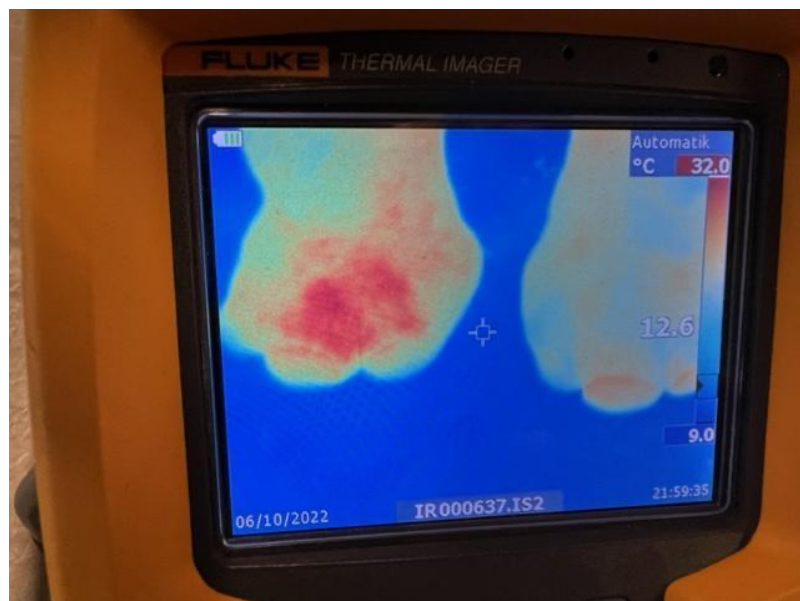
CO₂ increased from 53 to 68 showing hypercapnia. SO₂ dropped after exercise. The hypercapnia could be causing the hypoxemia. Possible causes of the hypercapnia are impaired gas exchange in the alveoli, which could be caused by decreased perfusion to part of her lungs, or thickened airways from bad airway disease such as asthma or COPD.

Elevated CO2 is not normally caused by an upper airway obstruction and expiration is not normally a problem with upper airways obstructions.

I witnessed no evidence of respiratory distress during any part of our exams and/or testing or walking around the zoo with her. As would be expected for any elephant exercising, her respiratory rate does increase when walking up a hill or after the game of “hide and go seek” but it was observed that even at these times of increased exertion she is not breathing with more effort or noise.

2) Abdominal and transrectal ultrasound performed by Drs. Goritz and Hildebrandt
Uterine mass and hyperechoic liver (hepatic lipidosis) were noted. See their full report for details.

3) Thermal imaging shows the areas of historical abscesses in the right front foot have increased in temperature, which suggests that area is a continued source of inflammation/ possible infection.



4) Trunk swab cytology (in house) 10/7/22. Significant amounts of Gram + cocci in chains and clumps, and Gram neg rods.

Trunk swab cultured *Streptococcus hyovaginalis* 4+ and *E. coli* 3+.

Discharge swab cultured *Enterobacter cloacae* 3+.

Resistance patterns were different for all.

The fungal culture results 1/2/23 cultured *Aspergillus nidulans* from the trunk swab, and nothing (no growth) from a swab taken from expelled mucus on the floor.

5) Last full blood work was performed on November 14, 2022. Results within normal limits.

Panelist Conclusion:

Assessment / Problem list

Obesity

Respiratory noise/discharge - cause still unknown

Pressure sores right ear elbow and hip

Malocclusion of molars

Arthritis/lameness

h/o Nail abscess right front

h/o Episodes of abdominal pain

Uterine tumor

Psychological well being

In my three days observing Lucy she was constantly surrounded by keepers and every single one of her movements was controlled/managed by her keepers, including where she urinates and defecates. It was exhausting to watch her be continually surrounded by people and constantly told to move on or have food hand fed to her even though she was already grazing, causing her to stop grazing to accept the food being offered by mouth. Lucy is being kept more like a pet and not being allowed to be the wild elephant she is. She is not being provided with the autonomy, space, socialization opportunities, or natural environment conditions she requires for her physical and psychological health.

Respiratory issues:

Despite the loud noises when breathing, I saw no evidence of respiratory distress during any part of our exams and or testing or walking around the zoo with her. Her resting respiratory rate is 4 breaths/minute which is normal for an elephant, however, it was noted that it was accompanied by a very loud rattling sound during expiration, which is unusual for an elephant. Normally you can barely see and cannot hear an elephant breathing, whereas Lucy's breathing can be heard anywhere in her barn and hundreds of meters away.

When walking up the hill to the dome, her respiratory rate did increase from 4 to 10 breaths/minute which is still within normal limits for an elephant and not tachypneic (fast). During her nap (lying down in the dome), her respiratory rate also increased (which is normal physiologically) to 6-8 breaths per minute. In lateral recumbency the breathing pattern has greater thoracic excursions and the respiratory rate can be discerned with ease. The normal respiratory rate for sleeping elephants is 3-8 per minute (Fowler, Mikota. *Biology, Medicine and Surgery of Elephants*, p. 296). Noises on inspiration and expiration could be heard but not with every breath, and the noise upon expiration was always louder than inspiration. There were a couple times while Lucy was sleeping when expiration did not have the loud rattling noise as it does when she is standing and awake.

Her loud noise upon expiration is very interesting because if an upper airway obstruction is suspected, as identified by all previous consultants, this is usually an inspiration not an

expiration problem. The high CO₂ seen on her blood gas is usually seen with a lower airway problem, which is also associated with expiration. This loud sound on expiration may be grunting which is an expiratory sound caused by sudden closure of the glottis during expiration in an attempt to maintain FRC and prevent alveolar atelectasis. But she also has almost a wheezing sound heard on inspiration.

Her long-term caregiver reports that her loud breathing started suddenly in 2004 and the noise has never really changed for better or worse since it started, despite a variety of medications Lucy has taken over the years. Courses of antibiotics, diphenhydramine, and mucolytic have been tried and now have all been discontinued as no significant change was seen in her respiratory rate, noise, or discharge from her trunk.

We observed Lucy doing a trunk wash procedure (typically done for TB testing). Interestingly, at no point did she attempt to drink with her trunk. She would allow the liquid to be poured into her trunk but made no attempts to suck the fluid up her nose. As well, during the procedure there appeared to be a location in her trunk that when liquid was present it almost seemed uncomfortable to Lucy. In those records to which I was granted access, I noted that endoscopies of Lucy's trunk have been performed 8 times since 2005, and unfortunately in none of these tests has the endoscope been inserted far enough to be considered diagnostic.

During this consultation, we reviewed the video of her last endoscopy on November 13, 2019 along with previous reports. Dr. Hildebrandt, who has performed hundreds of these procedures, did not feel the scope was ever passed far enough to visualize her larynx or erythroids (though reported to be visualized). Based on his experience, he also indicated that no one would be able to pass the scope far enough without the application of a local block which was never performed. To repeat the endoscopy with administration of a local block would require administration of standing sedation. Medetomidine and butorphanol would need to be used instead of oral diazepam which was used the previous two times. But most parties involved do not feel comfortable sedating Lucy this heavily due to her previous reaction to xylazine. In that instance her breathing slowed significantly, and she was trying to lie down in recumbency, which could be very dangerous for her breathing when sedated. Medetomidine has never been administered for sedation making it impossible to know if it would have a similar effect.

For a number of years the working theory initially suggested by Dr. Oosterhuis in 2009, was that Lucy's malpositioned teeth were the cause of Lucy's breathing problem, but several teeth have since fallen out and there has been no change or improvement in her loud breathing. Further, this hypothesis has not been borne out in the literature or through medical testing and is thus just a theory. Dr. Oosterhuis has been the expert repeatedly evaluating Lucy over the years a total of twelve times.

Asthma or COPD (chronic obstructive pulmonary disorder) are both possibilities that have not been explored to date. Neither condition has ever been reported in elephants but that doesn't mean it is not possible. Unfortunately, diagnosis of diseases of the lower airways require radiographs (which are not possible in elephants due to their size) and/or endoscopy of the lower airways to allow visualization and sampling (which is also not possible at this time with concern for sedating her). However, conditions such as asthma and COPD would not necessarily explain her open mouth breathing. Could her breathing problems be from the amount of time she spends in an old unventilated barn? Her harsh cold environment? Absolutely. I think it is very important that air quality testing be done of her current barn and updates/modifications undertaken according to test results and subsequent recommendations.

It is also highly possible that the cold dry environment may be adding to her respiratory problems. Especially with her tendency toward mouth breathing which doesn't allow her to warm, humidify, or filter the air she is breathing like she would if breathing through her nose.

Unfortunately, Lucy's loud open mouth breathing and "respiratory ailment" continues to confound and leaves us with many unanswered questions. With the concern of sedation as mentioned earlier, we may never be in a position to truly understand the cause and overall gravity of the situation. There is also the real possibility that even if she were sedated and it was possible to visualize her entire airway-tip of trunk into the lungs, that an answer wouldn't be obtained. There's no guarantee the test would reveal why her breathing is loud on expiration, the cause of her nasal discharge, and if there is a treatable diagnosis.

Urogenital:

Lucy has been noted to have had bloody mucoid vaginal discharge since April 2014 and even passing what appeared to be pieces of tissue in 2015. This is a very common condition for nulliparous (never have given birth) elephants in captivity. A study in an archival review of reproductive tract neoplasia, consisting of 80 adult female Asian elephant mortalities in managed care facilities in the United States from 1988 to 2019, found that neoplasms occurred in 64/80 (80%) of cases. Most were in the uterus (63/64; 98%) with only a single case of ovarian neoplasia. Myometrial leiomyomas were present in 57/63 (90%) cases with uterine neoplasia. Uterine adenocarcinoma was present in 8/63 (13%) cases. Remaining cases included endometrial adenoma (2), focal carcinoma in situ in endometrial polyps (1), anaplastic carcinoma (1), endometrial hemangioma (1), primitive neuroectodermal tumor (PNET; 1), and angiosarcoma (1). (Landolfi et al., 2021. *Reproductive tract neoplasia in adult female Asian elephants (Elephas maximus) Veterinary Pathology Vol. 58(6) 1131-1141*).

In addition to the continued vaginal discharge, Lucy has also been having frequent bouts of pain suspected to be abdominal (r/o Gastrointestinal vs urogenital) since 2010. Her discomfort has been managed through the use of a variety of anti-inflammatories and pain medications. In the medical records, vaginal endoscopy was recommended by specialists in 2018 and staff were told to start training Lucy to allow this procedure. Ultrasound is actually the preferred testing method to evaluate for uterine tumors, and could have and should have been performed in 2018 or sooner instead of training Lucy for endoscopy which delayed diagnosis. In 2022, when we arrived we were told she was still not comfortable to allow endoscopy. It was explained to Lucy's keepers that a rectal and transabdominal ultrasound could also be performed without sedation and that Lucy would probably allow both ultrasounds which she did very easily. Transabdominal ultrasound confirmed that Lucy's uterus is very abnormal and enlarged. Ultrasound does not allow the differentiation of a uterine tumor (malignant (carcinoma) vs benign (leiomyoma) which would require endoscopic biopsy to confirm but not necessary at this time.

Several elephants with the same condition have been successfully treated with GNRH vaccine which slows/stops the growth of the tumor. This will also hopefully relieve some of the probable abdominal pain she has been experiencing.

At the time of writing of this report Lucy has received 2 GNRH vaccines (treatment has been started since evaluation). First vaccine was given on October 17, 2022 and the second one

on November 22, 2022. The last observation/notation of bloody mucoid vaginal discharge was last noted on November 20, 2022.

Lucy has not displayed any episodes of pain (not eating/trying to lie down, stretching) since starting on firoxicab 454 mg PO SID in May 2020.

Obesity:

Obesity is defined as an accumulation of excessive amounts of adipose tissue in the body. All measures of adiposity involve defining body composition, or the relative amounts of fat versus lean body mass. Various techniques are available to measure body condition, and these differ in applicability according to the species of interest and the context of the Assessment.

According to the Body Condition Scoring (BCS) in *Morfeld KA, Meehan CL, Hogan JN, Brown JL (2016) (Assessment of Body Condition in African (Loxodonta africana) and Asian (Elephas maximus) Elephants in North American Zoos and Management Practices Associated with High Body Condition Scores. PLoS ONE 11(7): e0155146. doi:10.1371/journal.pone.0155146.)*, Lucy is a 5/5 and considered obese with ribs not visible, pelvic bone not visible, backbone not visible or difficult to differentiate, and area alongside backbone is filled in giving a round appearance.

In North American zoos, 74% of elephants (177 out of 240) had a body condition score above normal, with just 22% having a normal score. Obesity increases Lucy's susceptibility to foot and musculoskeletal issues.

According to her records, Lucy has weighed as much as 9445 lbs (recorded on October 3, 2022) and as little as 8120 lbs in 2012. Some of this weight could be from the large uterine tumor visualized on abdominal ultrasound which could possibly weigh anywhere from 100-200 lbs. Nonetheless, as every consultant has recommended since 2002, Lucy must lose at least 1000 lbs for her comfort and health. Her keeper's love, which is often attached to food/feeding, could play a significant role in further compromising her health and could well result in causing an early death.

It is imperative for her health, especially her arthritis, mobility, previous nail abscesses, and possibly her respiratory problems, that she lose weight slowly. The ideal body weight for an elephant of her stature is approximately 8100 lbs.

I would recommend discontinuing the beet pulp, as this is typically used in animals needing to gain weight, not those who are overweight. I would also recommend the feeding of monkey chow be completely discontinued, and to decrease the hay enhancer Mazuri pellets as much as possible. Other supplements can be researched to ensure Lucy is provided with the necessary vitamins/minerals. Other lower calorie/lower sugar fruits and vegetables can be added for training such as lettuce, celery, parsley, and fennel. Additional branches, grass, and/or bamboo should be given when possible and her current amount of hay offered should be decreased.

With some of the above recommendations already implemented, I am happy to report she has lost weight since the evaluation on November 7, 2022 and is now down to 8960 (recorded December 26m, 2022), from 9385 (recorded October 31, 2022).

Malocclusion of molars / undigested food in feces:

With Lucy's abnormal teeth position, it is imperative that her feces be monitored for increased size and decreased digestion of fodder. Her diet will need to be adjusted to offering smaller pieces of food and avoiding items that are lengthy and fibrous such as banana trees and long strips of bark. Food items with a laxative effect, such as bran and cooked pumpkin, can be added if she starts to have more trouble with constipation. Her hay could also be soaked and the browse cut up into smaller pieces before being offered.

Additional diagnostic tests recommended:

1. Air quality testing in the barn is strongly recommended as there is a high possibility that this could be adding to or exacerbating her breathing problems. As one previous report states she spends 67% of her time in the barn. Therefore, the ventilation in her barn must be checked and monitored on an ongoing basis for mold, particulates, dander, radon, asbestos, VOCs, chemicals, gasses, etc. Other issues of concern were the large number of pigeons seen, the condition of certain parts of the building (the keeper staff dissuaded me from using the bathroom in the barn because the ceiling was falling in), and the large number of rodents present.
2. TB culture (last performed on August 20, 2021, previously performed on May 12, 2017, and February 14, 2009) and possible PCR and serology for TB antibodies (has never been done).
3. Repeat foot radiographs (last done May 2019). The American Association for Zoos and Aquariums (AZA) recommends yearly foot radiographs for elephants with a history of chronic foot problems.

***Typographical Error:**
Should state "1000lbs" and not "10000lbs" - FTW



Medical Treatment recommendations:

1. Strict diet and slow weight loss, with a goal to lose 10000 lbs and maintain a weight of approximately 8100 lbs for an extended period would be ideal.
2. Continued GNRH vaccine as planned and monitoring of bloodwork and hormone levels. Monitor with repeat abdominal ultrasound in 6 months (April 2023) and 12 months (October 2023).
3. Consider a course of antifungal drugs and/or a different antibiotic for possible infection as the cause of her nasal discharge.
4. Consider a course of steroids (topical and/or inhaled) for possible asthma. Lucy would need to come off her NSAID first, which is controlling her episodes of abdominal pain. This is done out of concern for possible gastrointestinal ulceration with concurrent use of NSAID and steroid. Also consider administration of nebulized antibiotics/ bronchodilators.

Housing recommendations:

1. As Lucy spends the majority of her time in her barn, a much bigger barn, with better floor substrates (sand and padding) needs to be constructed. A barn with more natural sunlight and lamps that provide appropriate wavelength during the winter when days are so short is highly recommended. If keeping the current indoor enclosure, consider transitioning to all soft sand floor and one small concrete treatment area and/or add real rubber mats that can be cleaned. A taller, more well ventilated and insulated barn is in her best interest.

2. With her non-healing wounds on her right side, her sand bed needs to be switched to softer sand like that used for sandboxes.
3. Shifting to protected contact management, or at a minimum, less constant direct attention and contact to allow more autonomy, freedom of choice and the space and time to make her own decisions.
4. The Edmonton Zoo is lucky to have a large amount of land available that has not been developed. If Lucy was walked directly to this area and then just allowed to do what she wants including eating what she wants, without constant attention from her caretakers, this would be a significant improvement in her autonomy. If Lucy was given a much larger exhibit with her food placed around the exhibit, she would walk more naturally on her own and not require constant touching and guiding on walks through the zoo when weather permits.
5. Lucy should have access to running water at all times. Since Lucy only seems to drink from a hose, this may be more difficult but still possible. It is clear that she is either not able or does not want to drink with her trunk. Since she is only drinking from the hose this means she is not getting enough water the 12 + hours her caretakers are not surrounding her. An alternative needs to be in place to allow for proper hydration.
6. More cameras that can visualize all areas of her enclosure at night are needed. This will allow a review of night behaviors not only for sleeping patterns but activity at night. There is important information that can come from more thorough monitoring other than what side and how long she is sleeping for. It is extremely helpful to know what she is doing for the other hours when she is not sleeping.
7. A pool would be beneficial for Lucy, but because of the weather in Edmonton, it would have to be built indoors. Elephants generally will not submerge, get wet, or float unless it is warm outside. Careful consideration would have to be taken in the pool's design since if the entry ways are too steep and slippery, she could be reluctant to enter, and it could be dangerous. Some captive elephants have been forced/encouraged to go in newly constructed pools by bribing because millions of dollars were spent on construction or for public entertainment. Lucy would need to be given the full choice as to whether to enter the pool or not, for her own well-being and safety.

In summary, it is recognized that the staff seems very committed to taking care of Lucy. The zoo and local emergency responders appeared very prepared to mechanically lift Lucy if she were to go down and needed assistance to be raised to her feet wherever she would be located on the zoo grounds. I do think the current veterinary team is doing a good job monitoring Lucy, managing her pain, and has Lucy's best interest in mind with everything they do and recommend. They have been very welcoming and open to any and all suggestions made medical-wise for Lucy.

That stated, it should be acknowledged that I am making many of the same recommendations that have been made by almost every expert hired to consult on Lucy's health and well-being. It is concerning that despite the recommendations of different consultants (both for and against Lucy being relocated) the zoo has not followed through with treatment recommendations or modifications. They have also not made recommended updates to her housing environment, diet, or management that are believed would improve Lucy's health and welfare.

Part 2: Is Lucy Fit to Travel?

It is my opinion that it is possible to move Lucy and I do believe she should be moved for her health and welfare. The above listed health issues do not prevent her from being transported to a different, more appropriate environment. I witnessed no evidence of respiratory distress during any part of our exams and/or testing or walking around the zoo with her.

In an ideal situation, the Edmonton Valley Zoo management and staff would be working collaboratively with others who also bring extensive expertise, acquired knowledge and hands-on experience to the discussion in an effort to realize the best possible outcome for Lucy's physical and mental well-being – providing her with an environment that gave her the space and choice to live and thrive as an elephant. Collectively, we have the ability, and the responsibility, to ensure that her remaining years (that could easily be 15+) are well-lived as an elephant should with autonomy, room to roam and with others in her species. Lucy was born in the wild and although she is a captive wild elephant, she was born to experience life as an elephant and could do so if given the space and time.

Both the temperature and the decreased amount of sunlight in Edmonton creates an inhospitable and cruel environment for an Asian elephant. The forced walks on the snow and ice in -15C weather, borders on absurd. There is simply no way to provide Lucy with an appropriate life or the life she deserves in Edmonton. It needs to be clear that her life at the Edmonton Valley Zoo and those unwilling to relocate Lucy or even make the previously suggested changes, own responsibility in what will be her probable early death. The decision to keep her in Canada, in such an unnatural environment, while also not providing her with adequate housing conditions that would meet at least her minimal mental and physical needs is what has created the impoverished scenario Lucy now finds herself in.

Lucy deserves the chance to live a more natural life of an elephant. A life where she can walk around on her own and decide where she wants to go, when she wants to go, if she wants to stay in one spot grazing, or wants to keep walking and exploring. A life where she decides if she wants to lie down in the middle of the day and take a nap in the sun or under the moon and stars. If she wants to eat that tree bark now and that tree leaf later in the spring or if she wants to swim in the pond or not. And go to the bathroom whenever and wherever she wants. All choices that may seem 'small' but define who she is as an individual.

If Lucy's caretakers and zoo management wanted to move Lucy, I believe it could be done on a schedule to ensure Lucys' comfort and safety. I say this because to move Lucy with the least amount of stress, I do feel her current caretakers should be, and would need to be involved to help get Lucy used to the transport container, vehicle, and the entire process. Further, I would recommend that key caretakers accompany her on the move and remain at the new location until she is settled (or longer, if agreeable). Based on my observations of Lucy during the evaluation period, she is a very curious and calm elephant and I think she would be open to a new adventure, especially if her caretakers were excited and encouraging.

I have been the principal veterinarian during 5 elephant transports and have seen how each elephant adapts to the transport container differently. They can go from not entering at all, to backing in on their own and relaxing in the container given the time, reassurance, and reward needed to make it a positive experience. Some elephants can be nervous at first, but often very quickly settle into the transport. A route could be planned with emergency stop locations planned at zoos along the way to the sanctuary. A climate-controlled transport container with air conditioning and heat could also be built for her comfort. A transport container could be adapted to allow Lucy to have someone close to her during transport if it was something she appeared to need along the way. Supplemental oxygen could also potentially be available and provided, if necessary.

Possible New Home for Lucy

In my research, I explored the possibility and visited two elephant sanctuaries located in the United States – The Elephant Sanctuary (TES) in Hohenwald, Tennessee and Performing Animal Welfare Sanctuary (PAWS) in San Andres, California. Both are a full 2-3 day drive from Edmonton.

Upon closer examination of the possibility of Lucy moving to TES and PAWS sanctuary, I submit the following for consideration:

The Elephant Sanctuary – visited November 18, 2022	Performing Animal Welfare Society – visited November 11, 2022
2100 miles (3390 kms) from Edmonton – 34hr drive	1614 miles (2597 kms) from Edmonton – 24hr drive
Lucy would have access to hundreds of acres and interactions with other elephants (Asian and possibly African elephants at a shared fence) and would possibly share space with Sissy, an Asian female elephant who is TB negative.	Their only female Asian elephant has been treated for TB, so Lucy would not be able to join her. If she moved to PAWS Lucy would be alone though would potentially be able to interact with the two Asian bull elephants through a fence.
Specialized staff with focus on elephant welfare management	Specialized staff with focus on elephant welfare management
Advanced protective contact management system, that specializes in the care of geriatric elephants. Also provide ongoing care that includes yearly foot radiographs, oral exams, bloodwork, TB testing, along with daily care, observation, medicating, diet adjustments, and foot care	Advanced protective contact management system, that specializes in the care of geriatric elephants. Also provide ongoing care that includes yearly foot radiographs, oral exams, bloodwork, TB testing, along with daily care, observation, medicating, diet adjustments, and foot care
Space is readily available and there would be no cost to the zoo or the city to build out an enclosure.	Currently, PAWS does not have a yard or barn available, so this would require money and time to be built.
Global Federation of Animal Sanctuaries (GFAS) and AZA Accredited	GFAS Accredited

After visiting both sanctuaries, I think TES would be the best place for Lucy to relocate to. Based on the amount of space they have, barns available, number of staff/elephants they have, and variety of accommodations constructed for unique situations and the health and well-being of each individual elephant there, there is no reason to believe that they would not be able to provide the continued level of care Lucy needs and the attention Lucy may want from people.

Lucy will continue to receive the same medical treatments she does in Edmonton and probably have increased levels of care TES. The vet/animal ratio is 1/9 at TES and the sanctuary has sufficient resources to care for Lucy and many additional elephants. I do believe that TES has the staff of caretakers and veterinary team to provide Lucy with the attention she may want and need and/or the time, space, and freedom to decide what she wants to do when she wants to do. TES is already experienced with and in the process of treating an elephant for allergies.

At TES she will have the opportunity to have yards that she can graze in, a lake and multiple ponds she can swim in if she wants. Although most of the elephants' time is spent outdoors, she will also have access to a large, heated barn with both radiant and floor heat, sand beds, and thick poured rubber flooring in the stalls. During the spring and summer, the elephants at TES are able to consume approximately 85% of their diet off of the land so not requiring supplemental hay and diets; supplementation increases during the winter when not as much grass is growing for the elephants to graze on. The elephants have free access to the yards and stalls so they can decide where they want to be and sleep regardless of weather conditions.

Talking to people who have personally worked with several elephants who also had similarly extreme doting behavior from their zoo or circus keepers, the elephants changed within a short time after their arrival. They did not seem to miss an individual or the human interactions and instead began enjoying the freedom and autonomy, and most importantly, being with other elephants.

Potentially her respiratory problems are asthma and or allergy induced and could improve or completely resolve in a different climate and environment. As for her uterine tumors, as they are common in older elephants, it is highly likely that many elephants around the world are transported with uterine tumors; this alone is not a reason to avoid moving her. Almost every elephant in captivity has obesity issues and arthritis and repeatedly we see a dramatic improvement and change in mobility and gaining of muscle with moving to sanctuary. The ability and access to walk miles every day, diverse terrain, varied substrate, and the natural desire to explore and the mental stimulation a vast natural environment brings all play a role. Her arthritis should only improve in sanctuary versus the continued decline from standing and walking on hard surfaces like she currently does at the zoo. Her other medical problems can all be managed just as well at a sanctuary. The facility and staff are well equipped to handle any of Lucy's needs.

The real truth is no one knows how Lucy would do in transport, but we do know that she has suffered and continues to suffer where she is now. This is evidenced by her current physical condition as well as her lack of engagement in her environment – she is not thriving; she is merely surviving. There is nothing I witnessed during our multiple day assessment that would lead me to say she is not fit to travel. I do not think that sufficient evidence has been compiled for anyone to make that definitive statement. This is not to ignore, nor not carefully consider identified concerns; however, with careful planning and preparation a successful transport for Lucy is very possible. A team of experts, including her keepers, would need to acclimate her to the transport container and be with her during the entire journey to sanctuary.