

**J. E. OOSTERHUIS, DVM
VETERINARY CONSULTING SERVICES**

James E. Oosterhuis, DVM
Veterinary Consulting Services
P.O. Box 130
Ramona, CA 92065-0130

Phone: 619-972-1948
Email: jeo.dvm@cox.net

21 August 2015

ELEPHANT CONSULTATION REPORT

FOR

**EDMONTON VALLEY ZOO
EDMONTON, ALBERTA**

FOR

**FEMALE ASIAN ELEPHANT
“SKANIK”
(aka “LUCY”)**

ON

10 August 2015

REPORT CONTENTS

- **INTRODUCTION**
- **HISTORY**
- **OVERALL FINDINGS**
- **ORAL EXAMINATION**
- **EXAM OF FEET**
- **EVALUATION OF RESPIRATORY PROBLEM**
- **FACILITIES**
- **TREATMENTS**
- **ENRICHMENT**
- **WEIGHT CONTROL**
- **STAFF INSTRUCTIONS**
- **ASSESSMENTS**
- **PROPOSED PLAN**

J.E. OOSTERHUIS, DVM
VETERINARY CONSULTING SERVICES

James E. Oosterhuis, DVM
Veterinary Consulting Services
P.O. Box 130
Ramona, CA 92065-0130

Phone: 619-972-1948
Email: jeo.dvm@cox.net

MEDICAL/HUSBANDRY RECORD OF INSPECTION

**EDMONTON VALLEY ZOO
FEMALE ASIAN ELEPHANT
“SKANIK” aka “LUCY”**



**EDMONTON, ALBERTA
CANADA**

Date of Inspection: 10 August 2015
Species: Asian Elephant
Identification: Female, “Skanik” aka “Lucy”, age 40 years
Date of Report: 21 August 2015



“Skanik” aka “Lucy”

Introduction:

I examined the above elephant at the Edmonton Valley Zoo in Edmonton, Alberta, Canada on 10 August 2015. Present for the examination was Dr. Marie-Josée Limoges, Edmonton Valley Zoo’s Veterinarian and the Elephant Care Staff. This was my eighth examination of Skanik, a 40 year old female Asian Elephant who is also known as Lucy.

In July of 2002 the Zoo asked me to examine her and to evaluate the problems that she was having with her feet and to develop an action plan for her—which they followed and she returned to good health.

Then in September of 2009 I was asked to assess her overall health and to help them evaluate her respiratory problem that had recently developed and a retained, deformed molar tooth.

In January of 2011 I was asked to be present for another exam of Lucy’s respiratory issues and to attempt to collect diagnostic samples.

My latest exam of Lucy was done approximately 5 months ago on 23 March 2015.

This report is my written evaluation of her current condition as found by my exam done on the 10th of August 2015 and my recommendations for a continuing management plan for her.

History:

Lucy has lived at the Valley Zoo in Edmonton, Alberta for 38 years. She came to the Zoo as a two year old orphan.

In 2002 when I first saw her, she had foot problems that were solved by adjusting her husbandry program, increasing her exercise schedule and reducing her weight.


In 2009 I was asked to come to Edmonton to evaluate her for an abnormal molar tooth and a respiratory problem. The abnormal tooth had been shed by the time I arrived. At that time she was exercise intolerant to the point that she would have to breathe thru her mouth in order to catch her breath after a short walk. And when we explored her trunk with a 3 meter endoscope we discovered a narrowing of the nasal passages at the extent of the scope. A cause for the constrictions could not be determined because our view was obstructed by thick white exudate. It could not be determined if the tooth had any association with her respiratory problem. We determined at that time that her respiratory problem precluded her from being placed under any type of stressful situations, such as trying to move her to a different facility.

Since her respiratory difficulties continued, I was asked to be present for another exam by Dr. Milton Ness (former Edmonton Valley Zoo Veterinarian) and Dr. Jack Ingram (consulting Equine Veterinarian) on 31 January 2011. This exam revealed that her nasal constrictions continued, but the inflammatory process had diminished due to the treatment protocol that Dr. Ness had instituted.

This year, the Zoo requested that I come to Edmonton twice, once in Winter and now in the Summer, to examine Lucy and to examine her current condition and to evaluate her facilities and the staff’s management plan for her.

August 2015 Overall Findings:

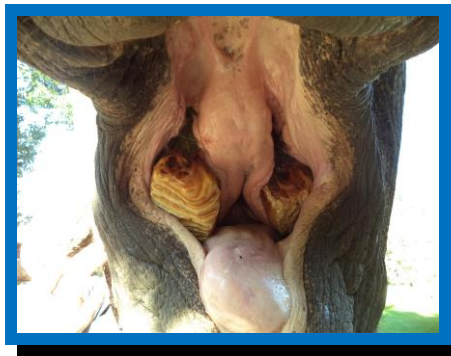
Lucy, as in past exams, is still a calm, gentle elephant that is managed in a “free contact” system. She is in excellent over-all condition thanks to the Elephant Care Staff’s diligence in following the current plan for her. She is at a weight that has increased a bit since last year, but still has good flexibility as evidenced by her ability to get up and down without effort. She still has some stiffness in her right carpus and left shoulder. Unfortunately, she still has a severe constriction of her nasal passages that affects her ability to breathe properly. The white exudate that was seen in 2009 continues to be greatly diminished. As before, if she walks too fast during her daily exercise, she has to open mouth breathe to restore her oxygen deficit. Elephants are obligatory nasal breathers, so to see an elephant breathe through her mouth is quite alarming. Simply walking her around elicited the open mouth breathing.



Lucy Exercising

Oral Examination:

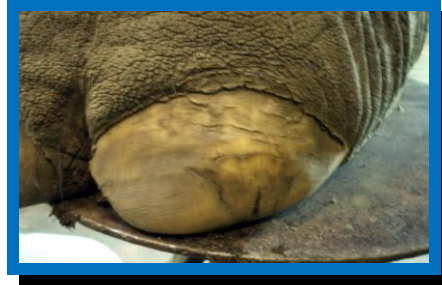On oral exam, she was noted to have a continuing deformity of both upper and lower molars. On this exam, the lower molars were briefly visualized and after reviewing the video that was taken by the keepers, it is evident that both anterior lower molars are retained and are being pushed to the side, without being exfoliated in a normal fashion. The right lower retained molar was palpated while Lucy was sedated, and was found to be slightly moveable. Both upper molars are abnormal in position and wear surfaces and appear to be static in that they have not advanced since the anterior upper molars were shed.



Lucy’s Upper Molars

Exam of Feet:



Examination of Lucy's feet reveals that she has had attentive care, as evidenced by her clean nails and the nice, well cared for cuticles. The staff should be commended for their efforts. She currently has no active nail or pad problems. She has evidence of the previous problem with her right front foot #2 nail defect, but it is not active at this time.



Lucy's Right Front #2 Nail

Evaluation of Lucy's Respiratory Problem:


As in the past examinations of Lucy, after a short walk, she has to breathe through her mouth in order to "catch her breath". Elephants, being obligatory nasal breathers, should never have to breathe through their mouths. This indicates that she continues to have a constriction in her nasal passages, despite the greatly decreased nasal exudates seen. On this examination, it was noted that she has increased respiratory effort when lying down, also.



Respiratory Difficulties While Walking and Lying Down

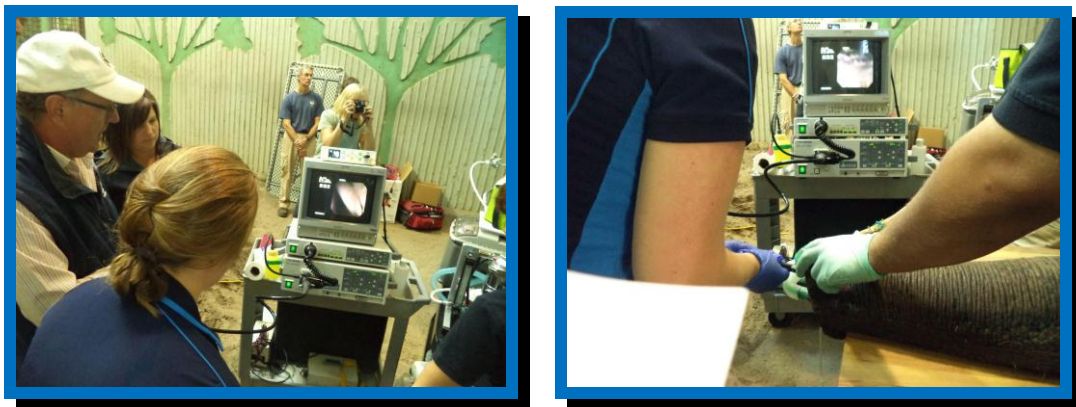Endoscopic Evaluation of Lucy's Nasal Passages:

On this examination, Dr. Jack Ingram, local Equine Specialist, was present to perform the endoscopic evaluation of Lucy's nasal passages. This was done after standing sedation was administered by Dr. Limoges. Due to our concerns for Lucy's ability to stand while under sedation, the Edmonton Fire Department rigged her with a custom made sling to catch her if she were to collapse while under examination.



Edmonton Firefighters with Lucy in the Support Sling

During the endoscopic examination with a 3 meter video endoscope, bilateral narrowing of her nasal passages was noted at 1.7 meters and again at 3 meters, but no obvious pathology was visible that could account for this narrowing at either level.



Dr. Ingram Scoping Lucy's Nasal Passages

Facilities:

Lucy's outside area consists of a large grass exhibit yard with a sand pile for resting, a pole structure, and shaded areas. She also has numerous exhibit enrichment items in her outside yard.

As part of the Plan for Lucy to increase her ability for exercise in the winter time, the Zoo built a 5,000 square foot heated building with a soft sand substrate several years ago. It continues to function well and is a great addition to the overall husbandry care of Lucy.

She will also go on walks in the Zoo with her keepers. The inside exhibit areas that are for public viewing, have a thick rubberized surface in the main viewing area and sand in the other areas. The rubber floor has held up well and except for some seam staining, is still intact.



Lucy's Outdoor Exhibit Area

Treatments:

Dr. Limoges currently has Lucy on a neutraceutical and an anti-inflammatory medication for her joint issues, and an expectorant and an antihistamine for her respiratory problem. She is also being treated with physiotherapy, exercise and Class 3B Cold Light Laser treatments for her stiff left shoulder. And they have continued her program of daily exercise for her overall general health.

I administered no medications during my inspection.

Enrichment:


As a solitary animal, the Elephant Staff have developed a program of enrichment for Lucy in lieu of another animal for her company. This includes the Keepers acting as her "herd mates", providing physical items, as well as mental stimulation as part of her husbandry program.



Exercise and Enrichment

Weight Control:

On this examination, it is noted that Lucy's weight is still up a bit, with her current weight listed at 4,400 kg (8,800 lbs). Even though she doesn't look over weight, the scales tell the story, so the Elephant Care Staff will continue to concentrate on trimming her down, with a Target Weight of 3,800 kg (8,400 lbs). Keeping her weight near the Target Weight and the exercise program have helped her to tolerate her respiratory problem. Reducing her weight will be the challenge for the Staff and will require strict adherence to her prescribed diet and frequent weights. Her good body condition is evidenced by comparing photos of her taken thirteen years ago in July of 2002 during my first exam and how she looks today.



Lucy: 2002 vs 2015 and as a Juvenile

Staff Instructions:

In my instructions to Staff, I reinforced the importance of movement, exercise and weight control in order for Lucy to better deal with her respiratory problem and any arthritic conditions that are present or may develop in the future. Feeding the prescribed diet is imperative, i.e. no food items that aren't on the approved diet list. She should continue to get tree branches to chew on and play with in order to see if we can get the potentially impacted right lower molar to loosen and exfoliate.

I commend the Elephant Care Staff on their dedication to give Lucy the best possible care that they can—both physical and mental. The Assessment section and the Proposed Plan section will detail my suggestions for the future.



Assessments:

- Lucy's good nature and the ability of the handlers to work closely with her, continues to be the key to her ability to handle her respiratory condition.
- Short of bringing in another elephant or some other animal, the staff has maintained their status as Lucy's "herd" members.
- I did not observe any abnormal behaviors or signs of being stressed. The only time that she seems stressed is if she walks too fast and can't catch her breath due to her respiratory problem.
- Her respiratory problem continues to be serious. The continual reduction of the exudates seen is encouraging. Unfortunately, her current respiratory difficulties when lying down may indicate that her nasal constrictions are getting worse.
- The fact that a constriction was detected on this exam at 1.7 meters, may indicate a change in the overall constriction pattern.
- Due to her breathing problems, stress or excessive exercise needs to be minimized. At the same time, **her controlled exercise program must be continued.**
- Lucy's weight has increased a bit and must be reduced over the next 12 months to her Target Weight. She should weigh between 3,700 to 3,800 kg (~8,100 to 8,400 lbs).
- The keepers are taking good care of Lucy's feet with their current foot care program. Currently, her feet are in the best shape that I have seen. Her past nail defects will probably recur in the future, despite the efforts by the Staff, as they do in many older Asian elephants, and quite probably will never completely disappear.
- Lucy's upper molars are deformed with abnormal wear surfaces. Both lower molars are impacted and are starting to deform due to retained anterior lower molars that have not exfoliated in a normal sequence. The right lower retained molar is slightly loose and it may be possible for the keepers to get it loose enough to be removed without an anesthetic procedure. I was unable to palpate the left lower retained molar to determine if it might be loose, also.
- As difficult and risky as it may be, due to her respiratory problem, we may have to consider an anesthetic procedure in the near future to surgically remove the retained lower molars and to try to re-shape the upper molars.
- The padding over the concrete floor of the indoor facilities continues to greatly reduce the abnormal pressures on Lucy's feet in the winter months. The additional sand area has worked out well, also.
- Overall, Lucy appears to be calm and well-adjusted in her current situation and is in good general condition for a 40 year old female Asian elephant, thanks to the care she gets from the Edmonton Valley Zoo elephant staff.
- However, her respiratory problem continues to be a severe problem that precludes placing her in any stressful situations.

Proposed Plan:

- **Respiratory Problem:**
 - Continue to treat this as a medical problem, for now.
 - Consider approaching the universities “bio-medical” engineers for help in developing biopsy instruments capable of collecting a tissue sample from an elephant via a 3 meter endoscope.
 - Continue periodic courses of antibiotics and anti-inflammatories as necessary to control the nasal exudate.
 - Repeat the endoscopic exam, under standing sedation once or twice a year. Or try to train Lucy to accept the scoping without sedation, so her condition could be evaluated more frequently.
- **Weight Maintenance:**
 - Evaluate the current prescribed diet and feeding protocols to see if it can be determined why her weight has crept up recently. Make corrections as necessary in order to get her back to her Target Weight of 3,700 to 3,800 kg (8,100 to 8,400 lbs) over the next 12 months.
 - Continue her exercise program—with care not to over-stress her so she has to open mouth breathe.
- **Foot Care:**
 - The Elephant Staff should continue their good foot care practices.
 - Periodic radiographs of her feet should be taken to monitor any arthritic changes that might develop.
- **Exercise:**
 - Continue Lucy’s exercise program despite her respiratory problem.
 - Be attentive to her need to catch her breath and if she has trouble doing so, discontinue the exercise session..
- **Periodic Mild Colic:**
 - Desensitize Lucy to rectal palpation, so rectal ultrasound can be done to evaluate her uterus for possible leiomyomas, which can cause pain and colic signs.
 - Perform monthly fecal evaluations for Occult Blood, which may indicate the presence of a gastric ulcer from the medications that she is on.
- **Dental Care:**
 - Train Lucy to open her mouth wider for better examination and photographs and videos of her upper and lower molars in order to better monitor their status.
 - Try to desensitize her to the use of a power dental float to re-shape her upper molars.
 - Continue to provide her with large branches to chew on to apply pressure to the impacted lower molars.
 - Attempt to loosen the retained right lower molar with a specially designed “crow bar” type tool.

End of Report

**James E. Oosterhuis, DVM
Veterinary Consulting Services
21 August 2015**